



PATIENT

Pip Kein

SPECIES

Feline

BREED

DLH

SEX

FS

AGE

7yr

WEIGHT

8.5lb

INTERPRETED BY

R. McKenzie Daniel,
DVM, DABVP
(Canine and Feline)

IMAGING PERFORMED BY

Grace Jayne CVT

HOSPITAL NAME

Ark Animal Homecare

REFERRING VET

Dr. Shalette Dingle

INVOICE 23511

DATE
01/12/2026

PRESENTING CLINICAL SIGNS

Presented for exam for possible URI. Reports that p had a cough but seemed to have resolved/improved significantly. Noticed audible breathing noted yesterday - sounds congested. Vomited plant material this morning. No nasal/eye discharge. Indoors only.

Abnormal PE/Chem/CBC/UA Results: Increased inspiratory lung sounds, cheek puffing on expiration and cheek puffing on abdominal palpation. Labs pending.

ULTRASONOGRAPHIC EXAMINATION OF THE ABDOMEN

Urinary System

The urinary bladder, trigone, cystourethral junction, and visible pelvic urethra to a depth of 2 cm exhibited normal thickness and tone. Anechoic urine was present in the lumen with minor hyperechoic, non-dependent urine sediment. The ureteral papillae were normal. The ureters were not visible which is normal. No evidence of inflammatory or neoplastic changes was noted.

Normal size and margination were present in the kidneys. A normal 1:3 cortex / medulla ratio and normal corticomedullary definition were maintained. The echogenicity of the cortex was similar to or slightly less than normal liver parenchyma while the medulla echogenicity was hypoechoic to the cortex with no evidence of pelvic dilation. The left kidney measured 3.7 cm in length. The right kidney measured 3.7 cm in length.

The area of the aortic trifurcation was free of pathology.

Adrenal Glands

The left and right adrenal glands were not definitively visualized. No obvious pathology was present in the area of the bilateral adrenal glands.

Spleen

The spleen exhibited a finely textured and homogenous parenchyma which was hyperechoic to the liver and renal cortical parenchyma. The capsule was smooth and regular without apparent expansion. The splenic vasculature at the hilus was normal in volume with no evidence of congestion or thrombosis. Acute to chronic inflammatory, neoplastic, or benign parenchyma changes were not noted.

Liver/Gallbladder

The liver was subjectively normal in size, structure, and contour. The liver parenchyma was uniform and hypoechoic to the spleen with a mild coarse echotexture. Normal vascular volume. The hepatic and portal vasculature were normal in appearance without signs of congestion. The gallbladder was non-distended in size with thin walls and primarily anechoic luminal content. The cystic and common bile ducts were normal.

Gastrointestinal

The stomach presented intact wall layering with a normal wall layer ratio. The lumen of the stomach was empty with no signs of ileus, obstruction or foreign material.



PATIENT

Pip Kein

The small intestine presented intact wall layering with 1:3 muscularis/mucosa ratio. The lumen of the small intestine was empty with no signs of mechanical/metabolic ileus, obstruction or foreign material.

Normal visible colon wall layers were present with apparent formed feces in lumen.

SPECIES

Feline

Pancreas

The parenchyma of the left limb, body and right limb of the pancreas presented isoechoic to the adjacent omental fat. A normal curvilinear capsule contour of the pancreas was present. The visible pancreatic duct was normal. No signs of active inflammation or neoplastic disease was evident.

BREED

DLH

Free Abdomen

No omental masses or peritoneal effusion was present.

SEX

FS

Intermittent mildly prominent to enlarged mesenteric lymph nodes were present. The lymph nodes were essentially isoechoic to adjacent omentum without evidence of peripheral inflammation and maintaining a normal width: length ratio (<0.5). An example measured 1.0 cm in diameter.

ULTRASONOGRAPHIC FINDINGS

AGE

7yr

Primary

- Sonographically normal abdomen.

WEIGHT

8.5lb

INTERPRETATION OF THE FINDINGS & FURTHER RECOMMENDATIONS

No evidence of visceral pathology as an obvious contributing factor to the patient's respiratory abnormalities. Correlation with pending lab work and thoracic radiographs is recommended.

INTERPRETED BY

R. McKenzie Daniel,
DVM, DABVP
(Canine and Feline)

IMAGING PERFORMED BY

Grace Jayne CVT

HOSPITAL NAME

Ark Animal Homecare

REFERRING VET

Dr. Shalette Dingle

INVOICE

23511

DATE

01/12/2026



PATIENT

Pip Kein

SPECIES

Feline

BREED

DLH

SEX

FS

AGE

7yr

WEIGHT

8.5lb

INTERPRETED BY

R. McKenzie Daniel,
DVM, DABVP
(Canine and Feline)

IMAGING PERFORMED BY

Grace Jayne CVT

HOSPITAL NAME

Ark Animal Homecare

REFERRING VET

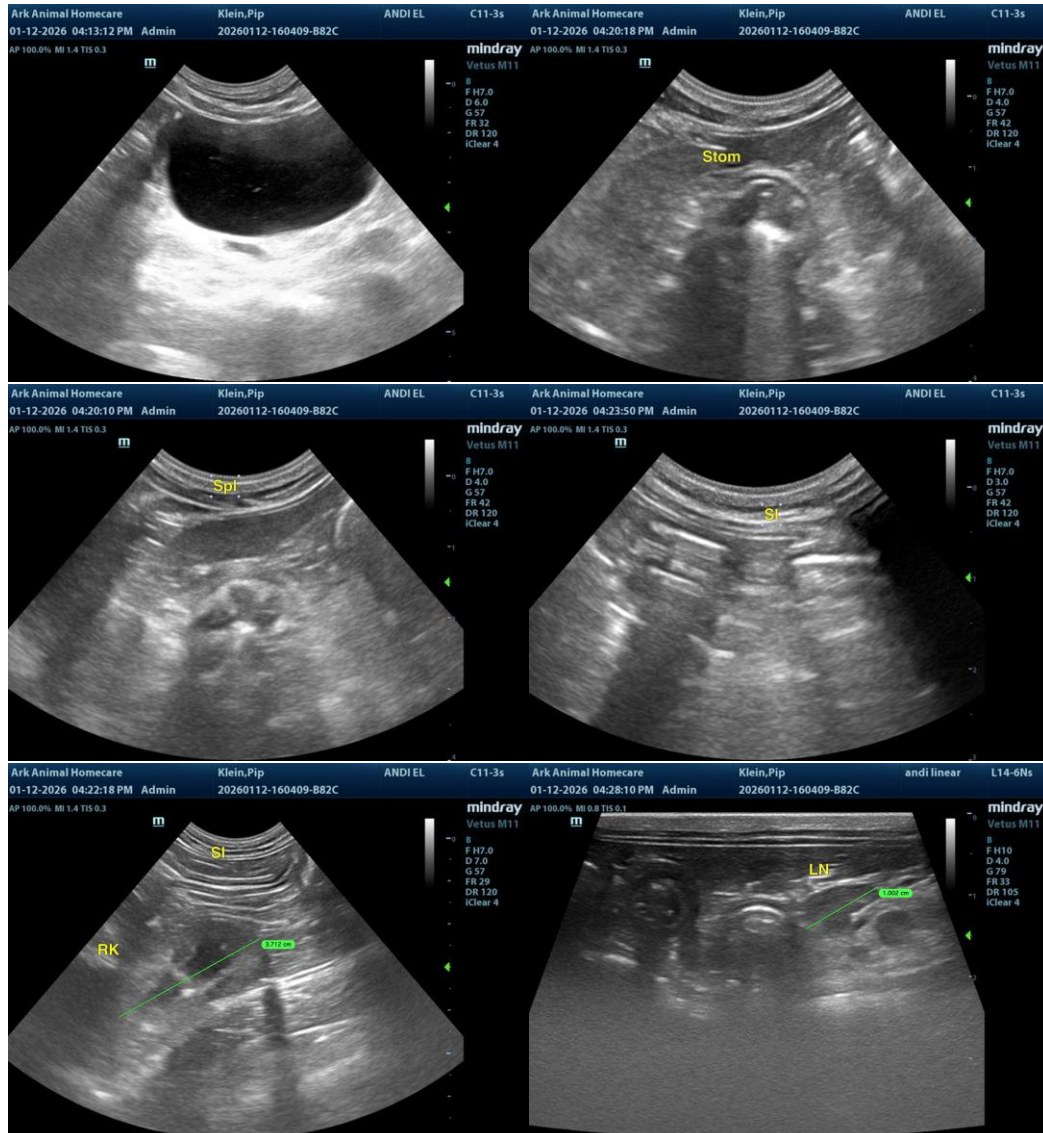
Dr. Shalette Dingle

INVOICE

23511

DATE

01/12/2026





PATIENT

Pip Kein

SPECIES

Feline

BREED

DLH

SEX

FS

AGE

7yr

WEIGHT

8.5lb

INTERPRETED BY

R. McKenzie Daniel,
DVM, DABVP
(Canine and Feline)

IMAGING PERFORMED BY

Grace Jayne CVT

HOSPITAL NAME

Ark Animal Homecare

REFERRING VET

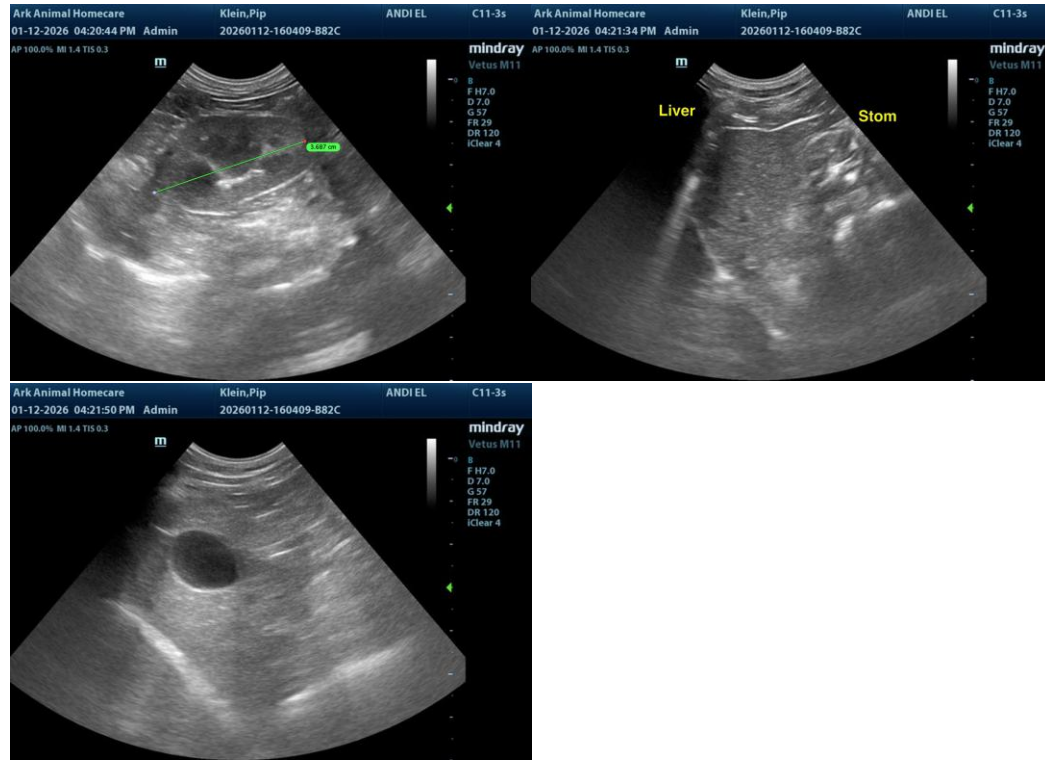
Dr. Shalette Dingle

INVOICE

23511

DATE

01/12/2026



The information and recommendations provided are based on the images presented by the referring veterinarian/sonographer. No evaluation can be communicated regarding pathology that was not visible in the image/video clips provided.

Thank you for this referral. If the clinical or image interpretation does not parallel your findings or if I can be of any further assistance, please contact me.

R. McKenzie Daniel, DVM, DABVP (Canine/Feline Practice)
info@sonopath.com